

# Urethrovesical anastomosis with single knot running suture in open retropubic radical prostatectomy. Experience with 536 cases.

Filipensky P.<sup>1</sup>, Pacik D.<sup>2</sup>, Rehorek P.<sup>1</sup>, Hrabec R.<sup>1</sup>, Cermak A.<sup>2</sup>, Varga G.<sup>2</sup>,

<sup>1</sup>Urology, St.Anne's University Hospital Brno, Brno, Czech Republic

<sup>2</sup>Urology, University Hospital Brno, Brno, Czech Republic

## INTRODUCTION:

The authors describe results of 536 consecutive nerve sparing open radical retropubic prostatectomies (RRP) performed by 3 surgeons, where the anastomosis was created with running suture. This technique described by Van Velthoven is commonly used in laparoscopic radical prostatectomy. In our center this method is performed also for open retropubic radical prostatectomy since September 2005.

## METHODS:

Between September 2005 and December 2012 536 RRP with „single knot running suture“ in urethrovesical anastomosis were performed. Two polyglycolic acid 2-0 sutures are used and tied together at their tail ends. A running suture is completed from the 5:00-o'clock position to the 12:00-o'clock position counter clockwise by first part and then clockwise to the 12:00-o'clock position by the second part of the suture, where they are tied together. The catheter is placed before completing the anterior row of sutures. Number of turns varies from 6 to 10 for one half of the suture. The water-tightness of anastomosis is tested by irrigation of 300ml saline solution. With regards to the evaluation of the benefits of this approach the following factors were followed up: operative time (skin to skin), time for anastomosis, water-tightness of anastomosis, duration of permanent catheterization, acute urinary retention occurrence after catheter removal, continence rate and development of anastomotic stricture.




Fig. 1. Two polyglycolic acid 2-0 sutures tied together

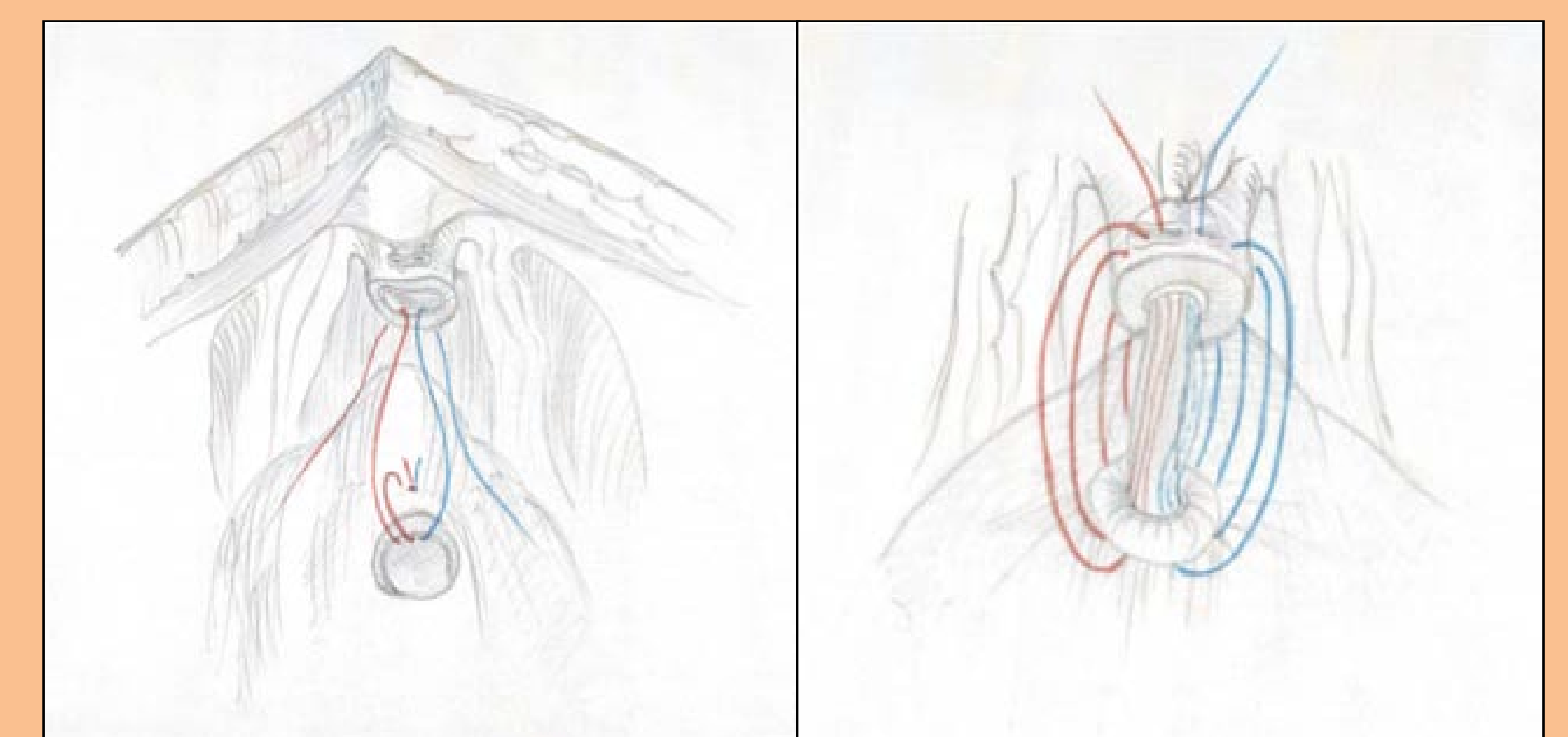


Fig. 2. Scheme of the anastomosis

Histologic findings	pT2a	pT2b	pT2c	pT3a	pT3b
Number of patients	73	62	277	87	37

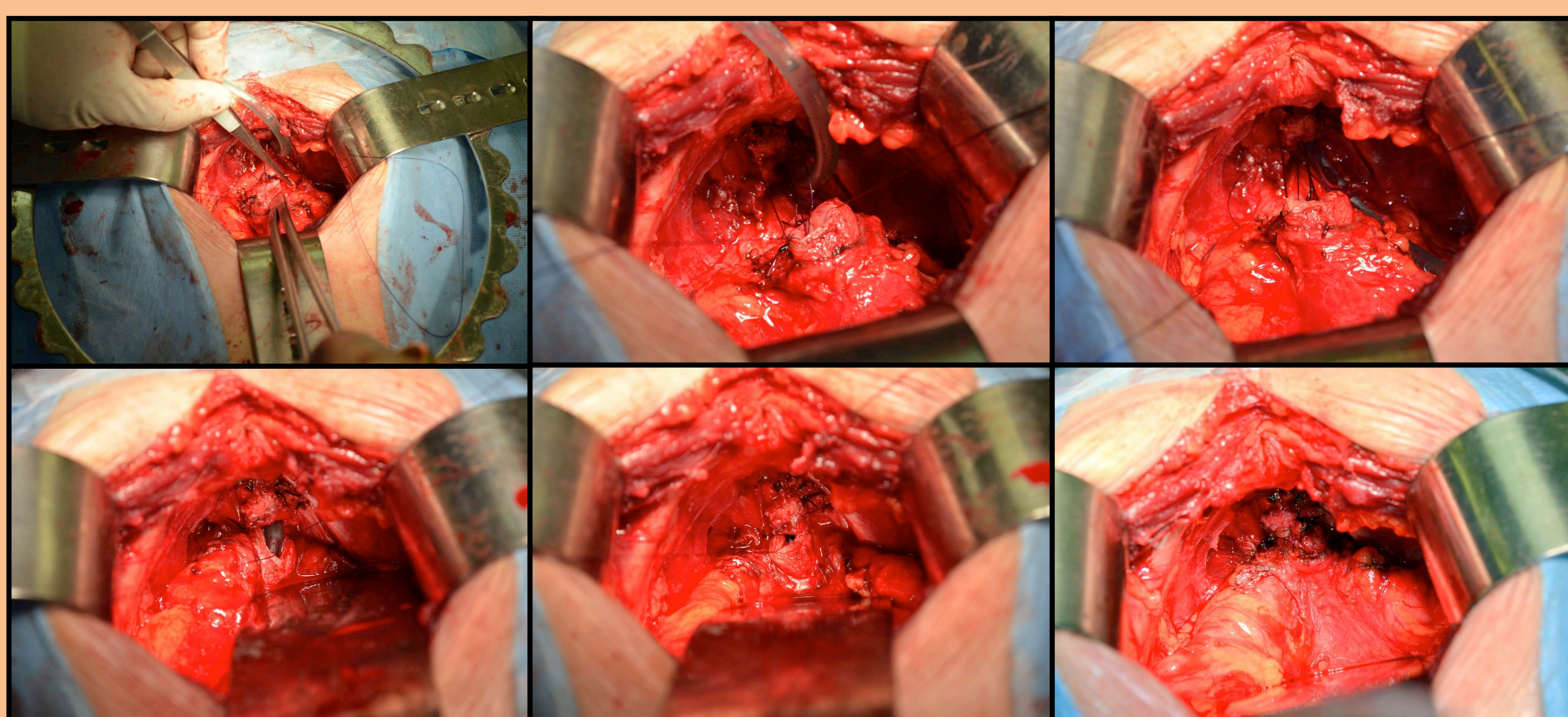


Fig. 3. Steps of the anastomosis

## CONCLUSIONS:

Single knot running suture during open retropubic radical prostatectomy is considered a feasible alternative technique for anastomosis creation associated with the following major advantages: reduced time to catheter removal in open technique (primarily), water-tightness of anastomosis and elimination of urethrovesical strictures. These improvements can have impact on satisfactory continence recovery.

## RESULTS:

The average time for surgery (skin to skin) was 77 minutes (range 42 to 153). The average time for the anastomosis was 9 minutes (range 7 to 20). In 5 cases (<1%) symptomatic postoperative urinary leaks have occurred, when the anastomosis could not be performed precisely. The catheter was left in place for 5 to 16 days, mean time 6,2 days. 12 weeks after RRP with running suture 78% patients were continent using 0 or 1 pad (security pad)/24hours. There were 3 clinically evident bladder neck contractures observed in our set – follow up time varies from 4-88 months. Bladder neck strictures were solved by ureterotomy with TUR of bladder neck.